

Clinical Report

MALOCCLUSION ASSOCIATED WITH ABNORMAL POSTURE

HIDEHARU YAMAGUCHI and KENJI SUEISHI

*Department of Orthodontics, Tokyo Dental College,
1-2-2 Masago, Mihama-ku, Chiba 261-8502, Japan*

Received 10 January, 2003/Accepted for Publication 9 April, 2003

Abstract

Growth and development of maxillofacial morphology and oral function are closely interrelated. Oral function is comprised of articulation, swallowing, and chewing. Malocclusion may be caused by abnormal functions such as mouth breathing, tongue thrust swallowing, and unilateral chewing and by abnormal postures of oral circumferential muscles such as forward tongue thrust, tongue biting, and low tongue at rest. Forces from unintentional and habitual behaviors constantly acting on the maxillofacial and alveolar regions can cause the bony structures to generally deform, resulting in jaw deformity and malocclusion. Oral function also plays a vital role in maintaining body posture. In this study, clinical observations of oral postures examined maxillary protrusion and open bite, anterior crossbite and facial asymmetry. The unstable forces induced by abnormal posture were correlated with the varieties of malocclusion. Morphology, function, and posture were shown to be closely interrelated and to influence each other.

Key words: Malocclusion—Abnormal posture—Oral function—Oral habits

INTRODUCTION

It has been said that genetically determined morphology and environmentally affected function are the two important etiological factors of malocclusion⁵⁾. It is well known that mandibular prognathism was prevalent in the Hapsburg family. This might have been due to some genetic factor causing mandibular overgrowth in this family⁹⁾. In general, a child's face resembles the parents'. There is no doubt that the growth and development of maxillofacial morphology are genetically determined.

Another factor is oral function, which

includes articulation, swallowing, and chewing. Malocclusion may be caused by abnormal functions such as tongue thrust, tongue biting, mouth breathing, low tongue posture, and unilateral chewing¹⁶⁾. According to Angle, a Class II division 1 malocclusion with maxillary incisor protrusion is related to mouth breathing, and a Class II division 2 malocclusion with a deep bite, to normal nose breathing. Thus, oral function and occlusion are closely interrelated. Graber *et al.*³⁾ said that morphology and oral function are as inseparable as the wheels of a car. Oral function also plays a vital role in maintaining body posture. It is generally accepted that forces from unin-

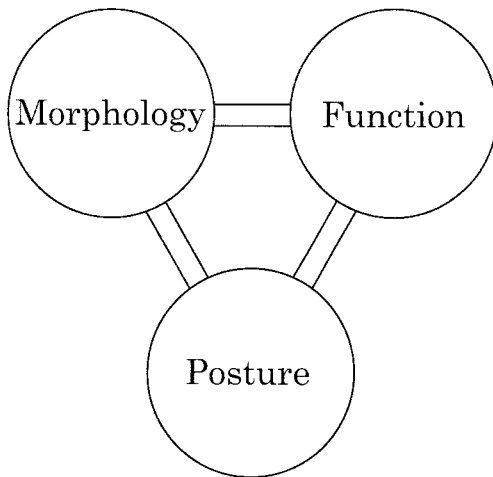


Fig. 1 Oral tripod of morphology, function and posture

tentional and habitual behaviors constantly acting on the maxillofacial and alveolar regions can cause the bony structures to gradually deform, leading to jaw deformity and malocclusion. These habitual forces are generally called abnormal posture. It is very important to examine the relationships between malocclusion and oral posture. The objective of this report was to explain the direct relationships among malocclusion, incorrect oral function and abnormal posture. The three factors, namely, morphology, oral function, and posture, are as closely inter-related as a tripod¹⁹⁾ (Fig. 1). The essential points of the treatment are also discussed.

CLINICAL OBSERVATION OF ABNORMAL POSTURE

1. Maxillary protrusion and openbite associated with abnormal posture

One of the abnormal habits causing maxillary protrusion or openbite is thumb or finger sucking²⁾. This habit is common among babies all over the world. Finger or pacifier sucking is a physiological behavior for babies that poses no problem. Until what age is digital sucking permitted as a physiological behavior? What about thumb sucking at age 2 years (Fig. 2)?

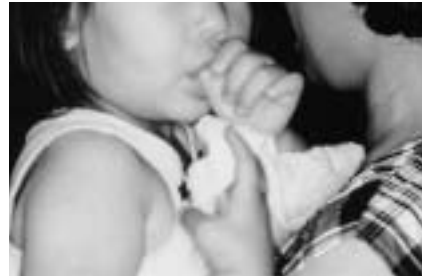

Fig. 2 Thumb sucking of a girl



Fig. 3 Two fingers sucking of a 10-year-old boy

Here we can see a slight hollow in the cheek created by her intense sucking of the left thumb. Her dentition was most likely compressed to the lingual side by the buccinator. In general, a child should not be forced to stop digital sucking until the age of 3 years. What if a 10-year-old boy is still sucking both the middle and third fingers (Fig. 3)? He has an anterior openbite with maxillary protrusion; the incisal edges are located above the occlusal line and have never come into occlusal contact (Fig. 4,a). It was estimated that his incisors were under constant pressure from finger sucking for 4–5 hours per day. We thought his habit should be stopped immediately. He himself also wanted to stop the habit and used a “tongue cage” (Fig. 4,b) as a habit breaker (Fig. 4,c). This is not an active orthodontic appliance; it simply prevents the tongue from protruding. He was instructed to wear it all the time for six months except when he was in school. As a result, the upper and lower incisors came into occlusal contact with an edge-to-edge relationship (Fig. 4,d),

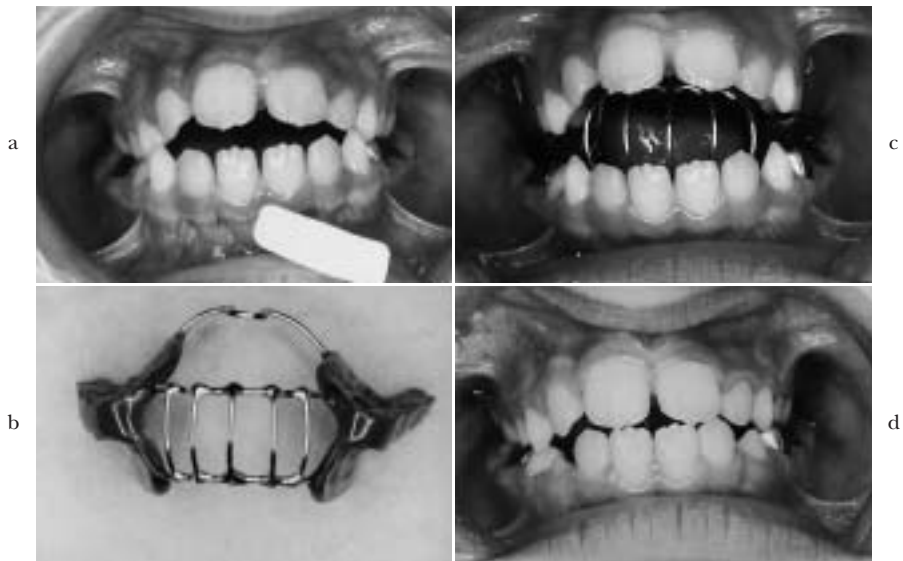

Fig. 4, a: Anterior openbite of 4 incisors
b: The tongue cage

c: Using the tongue cage
d: The edge-to-edge bite after corrected openbite

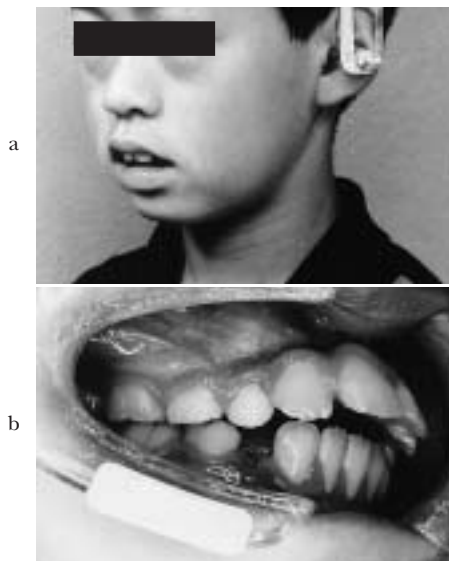


Fig. 5, a: Mouth breathing with opening lips apart
b: Maxillary protrusion with 7 mm of overjet

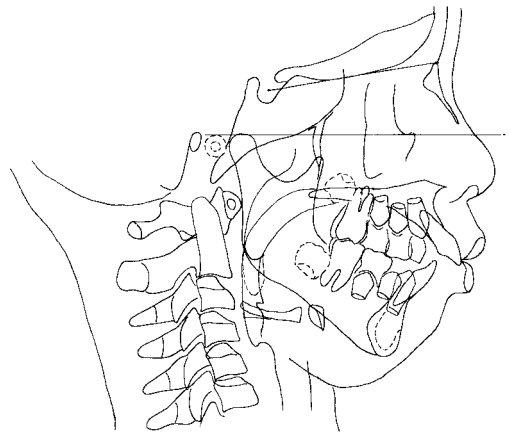


Fig. 6 The cephalometric tracing of maxillary protrusion

demonstrating that the cessation of digital sucking was effective in treating the openbite. Digital sucking may have caused the openbite in this case. The above experience seems to support the idea that oral habits such as digi-

tal sucking and tongue thrust can affect jaw morphology, occlusion, and dentition¹⁰.

Most patients with maxillary protrusion breathe through their mouths with the lips slightly apart at rest. Why do mouth-breathers

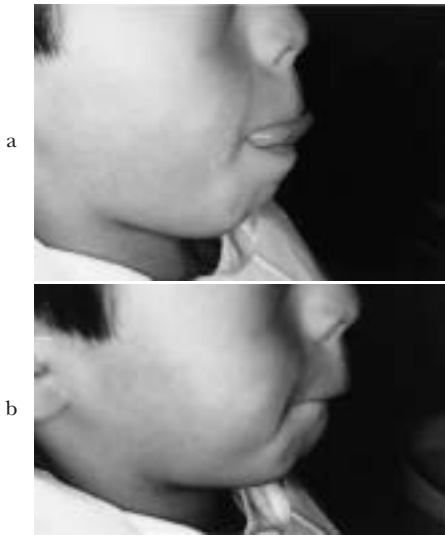


Fig. 7, a: Tongue thrust and lip licking
b: Lower lip sucking

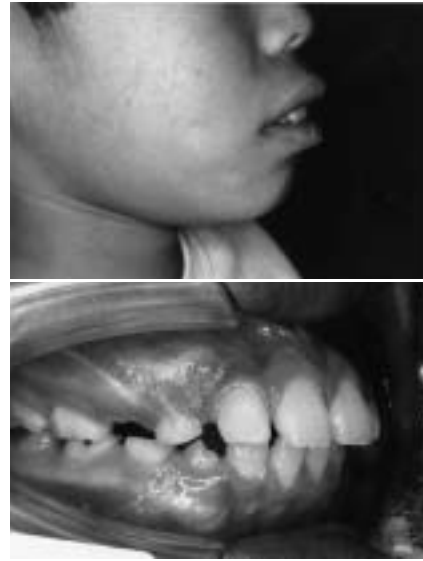

Fig. 8, a: Opening lips and mouth breathing
b: Bi-maxillary protrusion and interdental spaces

develop maxillary protrusion with labially inclined upper incisors? The 9-year-8-month old boy shown in Fig. 5-a held his lips apart slightly. He had 7 mm of overjet and -1 mm of overbite in centric occlusion (Fig. 5,b). He was in the mixed dentition period and of a vertical type with the second deciduous molars on the terminal plane and a Class II molar relationship. The upper arch was V-shaped with interdental spaces anteriorly. Lateral cephalometric analysis revealed mandibular retrusion (Fig. 6), an abnormal jaw relationship with 7° of ANB, and labial inclination of the upper and lower incisors. The examination of orofacial muscles showed mouth breathing with open lip posture and inadequate muscle tone at rest¹⁾. He often thrust the tip of his tongue and licked his lips during mouth breathing (Fig. 7,a). The habits of tongue thrust and lip licking were so closely interrelated that the lower lip was sucked hard into the oral cavity following tongue thrust (Fig. 7,b). He therefore often bit his lower lip with his upper and lower anterior teeth, pushing the upper anterior teeth labially¹⁰⁾. He also exhibited a habit of sucking his lower lip during saliva swallowing.

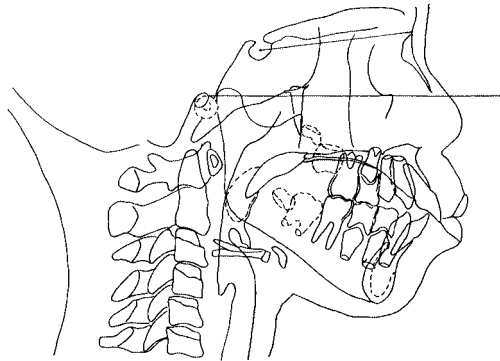


Fig. 9 The cephalometric tracing of bi-maxillary protrusion

An 11-year-8-month old boy had the protrusive upper and lower lips often seen among Orientals. The lips were always parted for mouth breathing (Fig. 8,a), and the anterior teeth were showing between the incompetent lips. The molar relationship was toward a Class II tendency (Fig. 8,b). The upper dental arch was V-shaped with interdental spaces. Lateral cephalometric analysis demonstrated a very small interincisal angle of 106° due to labial inclination of the incisors (Fig. 9). He was diagnosed as a typical dental bimaxillary

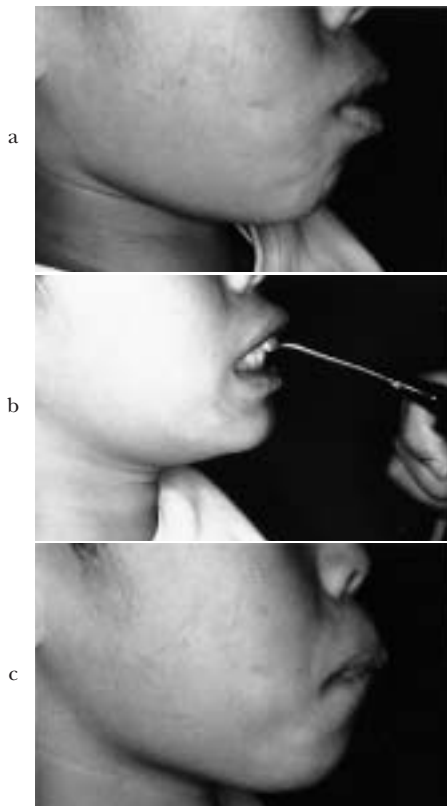

Fig. 10, a: Speaking with muscle strain and lips protruding
 b: Shooting water
 c: Strong tension of lips with swallowing

protrusion. He could not keep the lips closed even for a minute due to nasal obstruction. He protruded the lips further with excessive mentalis strain during speech (Fig. 10,a). Abnormal strain of the oral muscles was also frequently observed during swallowing⁷. The lower lip was sucked into the oral cavity upon shooting of water into the oral vestibule (Fig. 10,b). Swallowing of water was accompanied with severe lip strain, pushing the upper anterior teeth forward and further increasing the protrusive appearance (Fig. 10,c). This posture is called lip incompetence during swallowing.

The smiling girl aged 6 years 7 months shown in Fig. 11-a was in the mixed dentition period with deciduous incisors being replaced with permanent incisors. She had a low tongue habit, and the tip of the tongue protruded

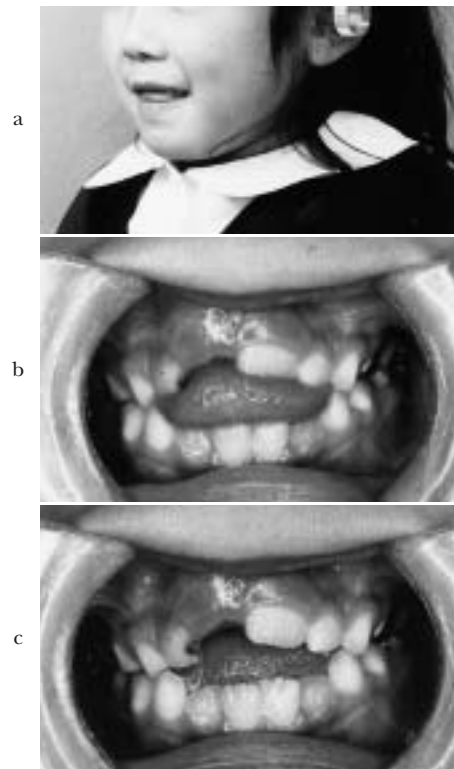


Fig. 11, a: Smiling with tongue protruding at 6 years 7 months
 b: Tongue thrust forward
 c: Anterior openbite with a step between deciduous canine and incisors

into the space between the upper and lower anterior teeth at rest (Fig. 11,b). With a step between the lower deciduous canine and permanent lateral incisor, the four lower incisors were below the occlusal line (Fig. 11,c). She had a long face and a weak bite force. According to her mother, she continued to suck her thumb until 3 years of age and has had an openbite since early childhood. She had an infantile speech pattern lacking in clarity⁴. Since she herself was unaware of tongue thrust at rest, a decision was made to simply watch her until she became mentally mature. The intraoral photograph taken at age 8 years 6 months (Fig. 12,a) depicted a persistent anterior openbite and tongue thrust despite the eruption of the upper lateral incisors. She was ready to stop tongue thrust and was therefore given a tongue guard designed to break

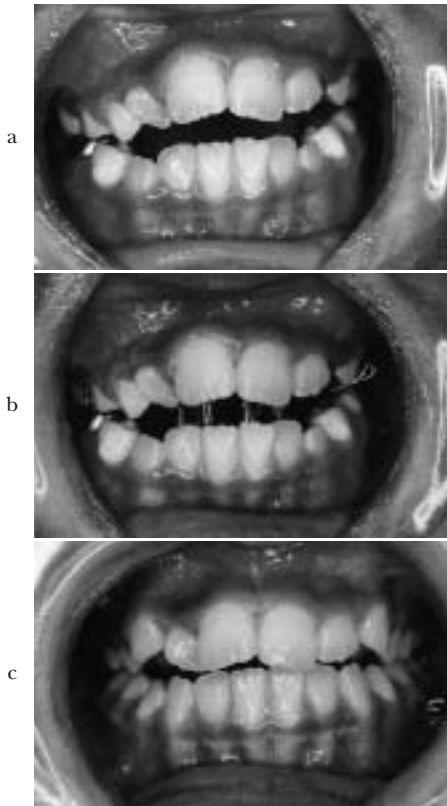


Fig. 12, a: Anterior openbite at 8 years 6 months
 b: Using the acrylic plate with tongue guard
 c: Contact between upper and lower incisors

the habit (Fig. 12,b). After one year and 3 months, she was able to bring the upper and lower incisors into occlusal contact (Fig. 12,c). To prevent relapse, she was reminded of the importance of lip seal and nose breathing¹²⁾. She is scheduled for orthodontic treatment with a full appliance to establish an individual normal occlusion after the eruption of permanent premolars.

Another type of tongue thrust is lateral thrust (Fig. 13,a); the side of the tongue thrusts between the upper and lower deciduous molars or permanent premolars. Lateral openbite becomes evident only when the tongue is retracted from between the teeth (Fig. 13,b). This is one of the difficult habits to detect because the patient is not aware of it. Lateral tongue thrust may interfere with the eruption of premolars and depress the teeth

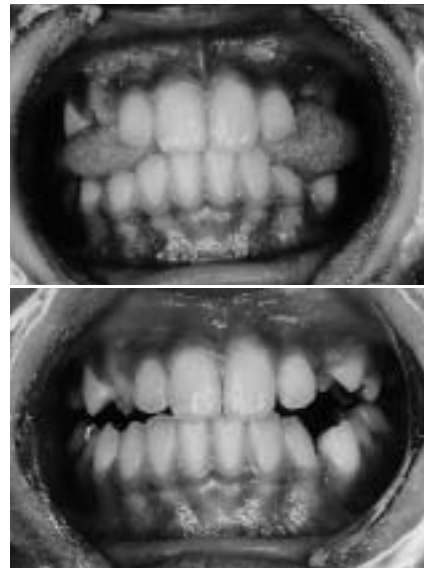

Fig. 13, a: Lateral tongue thrust
 b: Lateral openbite

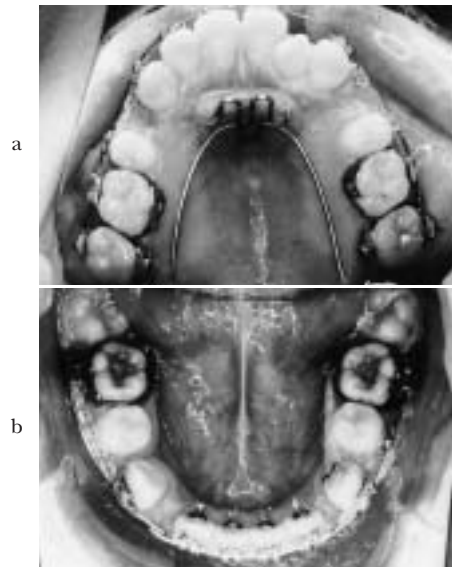


Fig. 14, a: Nance's holding arch with tongue guard
 b: Tongue crib bonding at lingual surface

in the buccal segment into the alveolar bone, creating lateral openbite. The absence of such a habit facilitates the second phase of orthodontic treatment and shortens the treatment time. There are various types of tongue

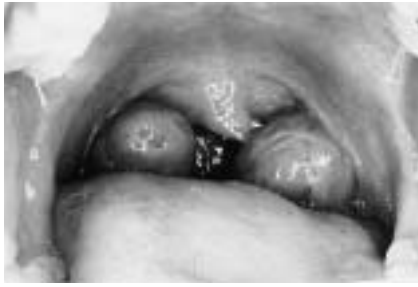

Fig. 15 Large tonsils of palatine

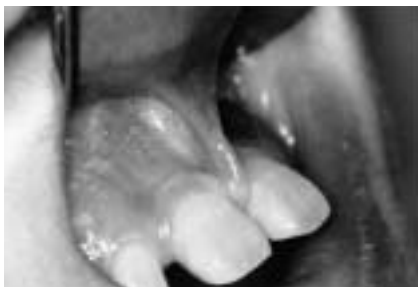

Fig. 16 Short upper lip frenulum

guards: an acrylic plate with a tongue guard embedded (Fig. 12,b), a Nance's holding arch with a tongue guard embedded in resin button (Fig. 14,a), a lingual arch soldered a tongue guard, a tongue crib bonded to the lingual surfaces of the lower anterior teeth (Fig. 14,b), and a tongue cage (Fig. 4,b). Other factors inhibiting normal growth include large palatine tonsils causing lip incompetence (Fig. 15) and diastema due to a short upper lip frenulum (Fig. 16). If these problems are causing deformity or malocclusion, detailed examinations should be made to find and perform an appropriate treatment.

2. Anterior crossbite associated with abnormal posture

Anterior crossbite results from an antero-posterior skeletal discrepancy between the maxilla and mandible and improper axial inclinations of the anterior teeth. Many patients with anterior crossbite have a Class III molar relationship in centric occlusion due to a protrusive lower arch. There is a fear of

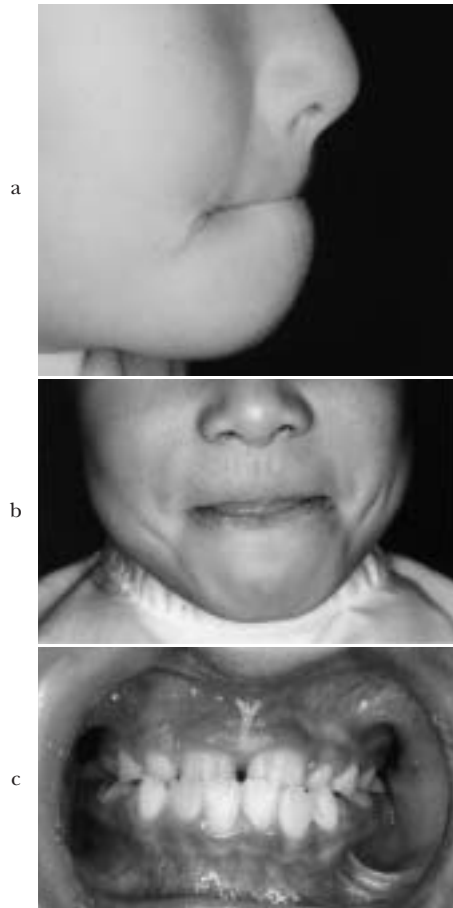


Fig. 17, a: Lip sucking of upper and lower lips
b: Lip sucking and dried lips
c: Anterior crossbite

anterior crossbite in childhood gradually progressing to a more severe skeletal deformity. Why does the malocclusion increase in severity from dental to skeletal?

Normally, the lips are relaxed and lightly closed at rest. Anterior crossbite is often associated with severe perioral muscle strain during swallowing of water or chewed food. The upper lip or both lips are sucked into the oral cavity with strong pressure during oral function¹³⁾ (Fig. 17,a). In particular, upper lip sucking is frequently seen in these patients. The upper lip is sucked strongly into the oral cavity as it is drawn in with the lower lip. Subsequently, the lips get dry and chapped, caus-

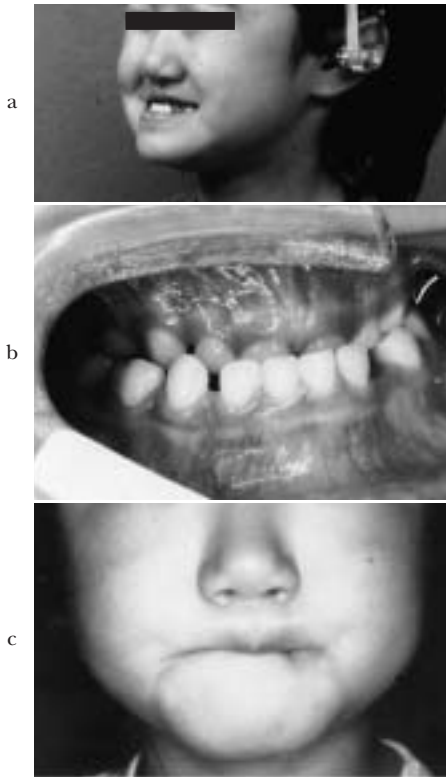


Fig. 18, a: Smiling: the severe concave facial type
 b: Anterior crossbite with -8 mm of overjet and 5 mm of overbite
 c: Lips sucking with strong tension

ing lip licking to wet the lips and creating a vicious cycle of lip licking and chapped lips (Fig. 17,b). During this process, the upper lip pushes the anterior teeth back, tipping the upper incisors lingually. Lip sucking is also accompanied with a slight forward movement of the mandible and upper lip biting with the lower anterior teeth. This patient (Fig. 17,c) has a Class I molar relationship with the four incisors in crossbite. Her bite force is very strong, and her vertical overbite is about 5 mm . Some patients with anterior crossbite have a habit of sucking both lips simultaneously into the space between the upper and lower anterior teeth (Fig. 17,a). Kydd *et al.*^{7,8)} found that the labial surfaces of the incisors can be subject to over 200 g/cm^2 of lip pressure, larger than typical orthodontic force. Although the habit of sucking both lips is very

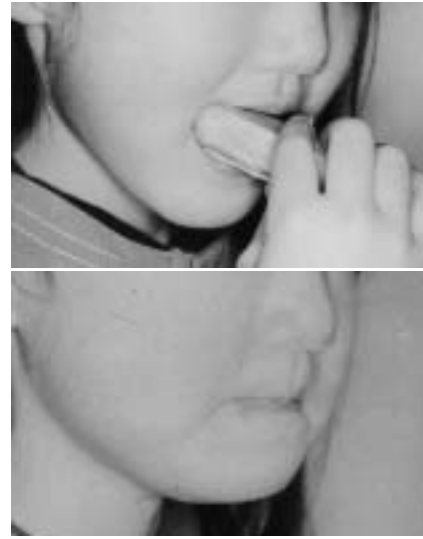

Fig. 19, a: Chewing of a pancake
 b: Lip sucking during swallowing

similar to upper lip sucking, the amount of lip pressure applied to the teeth by both lips seems to be larger than that by the upper lip alone¹¹⁾. The vermilion of either lip becomes totally invisible. Lip sucking immediately follows the lip licking subsequent to tongue thrust.

A girl aged 4 years 5 months with anterior crossbite showed an extremely concave profile with an underdeveloped mid-face and a protrusive chin (Fig. 18,a). She had -8 mm of overjet and a deep overbite of 5 mm (Fig. 18,b). Her speech was characteristic of low tongue posture, and there were tooth marks along the sides of the tongue. Generally, the tongue of a child with anterior crossbite is hypoactive and in a low postural position, leading to unclear and infantile articulation. This girl was sucking both lips strongly into the oral cavity (Fig. 18,c) while listening to others. The vermilions of both lips were invisible, and the mandible protruded during lip sucking. This act of lip sucking following lip licking was frequently seen when she was at rest. She also exhibited this habit of licking and then sucking the lips into the oral cavity during chewing and swallowing of a pancake

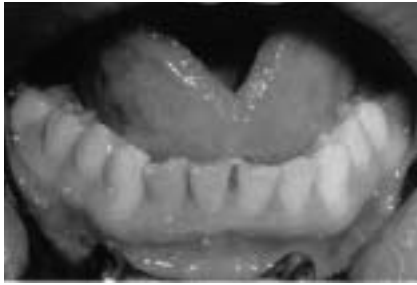

Fig. 20 Short lingual frenulum

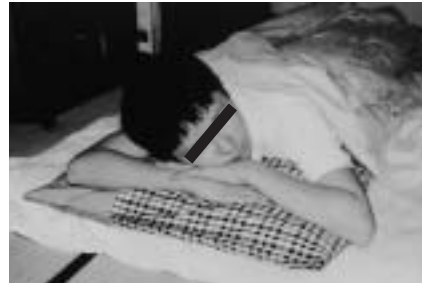

Fig. 22 Sleeping style on the stomach

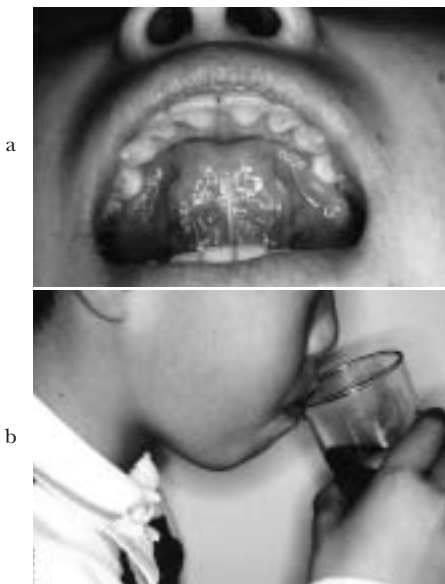


Fig. 21, a: Tongue up to the spot
b: Drinking liquid from a glass

(Fig. 19,a). Her perioral muscles were severely strained for lip closure. Her tongue stayed on the floor of the oral cavity during chewing. She also showed excessive strain of the lips and facial muscles every now and then when she swallowed chewed food^{8,14} (Fig. 19,b) or drank water from a glass.

Another cause of anterior crossbite is a short lingual frenulum that limits tongue movement and keeps the tongue low (Fig. 20). Low tongue posture facilitates forward positioning of the mandible and development of a reverse overjet. A short lingual frenulum,

if found in pre-school or school children, should be elongated with frenectomy.

For correction of low tongue posture, there are myo-functional therapy (MFT) exercises developed by Zickefoose such as 'spot' training that raises the tip of the tongue^{18,20}. The 'spot' position is near the incisive papilla in the anterior part of the palate²¹ (Fig. 21,a). Another important mode of treatment for patients with low tongue posture is speech therapy that involves keeping the tip of the tongue on the 'spot'. A training method to keep the tip of the tongue on the spot should also be provided. In addition, drinking water from a glass with the lips lightly closed is very effective (Fig. 21,b). Since most patients with anterior crossbite exert strong bite force and lip pressure upon lip closure, it is better not to include oral muscle training in an MFT program.

3. Facial asymmetry associated with abnormal posture

An infant's facial shape, whose morphology is genetically determined, closely resembles those of the parents. The environment also influences morphology during growth; one example is sleeping on the stomach, which is said to strengthen the respiratory system and increase the muscle activities of the limbs. This photograph (Fig. 22) shows a boy sleeping on his stomach on a Japanese-style mattress called a "futon". His face is turned to the left with the right side of the chin placed on the back of his hand over a pillow. His chin is under lateral pressure to the left as long as he



Fig. 23 Resting the chin on the palm of the hand

sleeps in this style. It is likely that he sleeps in this position for several hours per day. Suzuki *et al.*¹⁷⁾ found that the amount of pressure applied to the chin is 2–4 kgf because of the weight of the head. The work done, a product of acting force multiplied by the duration of action, amounts to a large value, which is applied to the lateral part of the chin every day. It has been reported that the long-term use of a chin cap causes the neck of the condyle to bend. If the mandible is constantly placed under significant lateral pressure for several years, the chin may be bent in the direction of the force, resulting in facial asymmetry. Lateral force thus constitutes a possible cause of maxillofacial deformity with asymmetry.

The habit of resting the chin on the palm of the hand also puts a lateral force on the mandible. This boy is reading a book by resting the chin on the palm of the left hand (Fig. 23). He sometimes watches TV for several hours in the same habitual posture. The weight of the head is applied to the left hand, while the anterior part of the mandible receives the reaction force. The amount of pressure applied in this case is as large as that during sleeping on the stomach. These habits that exert lateral force on the mandible take place frequently and for a significant amount of time in daily life; they may alter the direction of mandibular growth in childhood and result in facial asymmetry with lateral deviation of the mandible. The teeth on the side to which the chin deviates will be in posterior crossbite. Another habitual posture associ-

ated with lateral force is unilateral chewing. Unilateral chewing of food in everyday life may cause a lateral tilt of the occlusal plane with one side higher than the other and a deviation of the lower dental midline to the chewing side. This is one of the deformities related to habitual behaviors. Another habit leading to postural imbalance of the body is that of always hanging a heavy bag on the same shoulder. The shoulder carrying the bag is raised higher than the other, which causes the spinal axis to slightly bend to one side to correct the body balance. In addition, the head becomes tilted to adapt to the change in body balance, and the cervical muscles supporting the head adversely affect the occlusion. Thus, abnormal external forces can cause jaw deformity with mandibular deviation and facial asymmetry during growth of the jaw bone⁶⁾.

DISCUSSION AND CONCLUSION

Maxillary protrusion and openbite in childhood are related to abnormal habits of digital sucking, tongue thrust, lip licking, lip sucking, and mouth breathing, etc. Since these habits differ in frequency, amount of pressure, duration, and method, the way that malocclusion develops varies from one individual to another. Resultant morphological abnormalities depend on the effects of dysfunction and abnormal posture. The three factors of morphology, function, and posture influence each other, contributing greatly to the continued growth and development of normal occlusion and a balanced face¹⁵⁾.

The series of abnormal behaviors at rest ranging from lip licking and tongue thrust to lip sucking are observed in many, if not all, children with anterior crossbite. These habits further augment the prognathic tendency. Their abnormal swallowing pattern also has a major impact on their dentition. The upper anterior teeth are pushed back by the upper lip during the cycle of chewing and swallowing, which decreases overjet. These postural habits in childhood therefore seem to con-

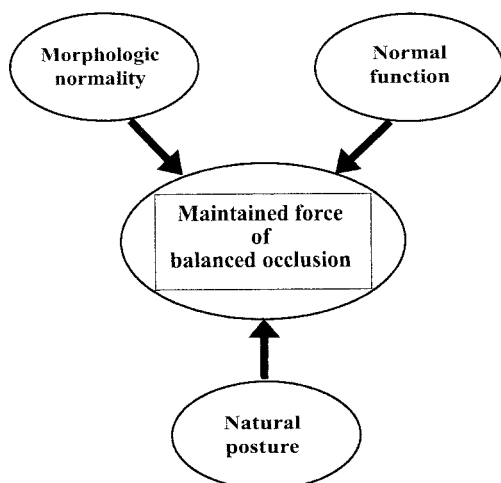


Fig. 24 Tripod supporting morphology, function, and posture

tribute greatly to the development of anterior crossbite. It is very important to advise children to refrain from tongue thrust, lip licking, or lip sucking at rest.

The shape of the jaw bone undergoes gradual changes in response to external forces. Effects of lateral force on the dentition and occlusion depend on the mode, frequency, duration, and degree of force application as well as environmental factors, which differ from one individual to another. It is very important to pay close attention to natural muscle and body postures in order to allow growing children to acquire a normal balance in every aspect as part of a sound life style. Forces that maintain a well-balanced occlusion are generated through normal morphology, normal function, and natural posture¹⁹⁾ (Fig. 24). These factors interact to maintain a normal occlusion and a pleasing facial profile. The three factors are as closely interrelated as a tripod.

REFERENCES

- 1) Andrianopoulos, M.V. and Hanson, M.L. (1987). Tongue-thrust and the stability of overjet correction. *Angle Orthod* **57**, 121–135.
- 2) Gale, E.N. and Ayer, W.A. (1969). Thumb-sucking revisited. *Am J Orthod* **55**, 167–170.
- 3) Graber, T.M., Chung, D.D.B. and Aoba, J.T. (1967). Dentofacial orthopedics versus orthodontics. *J Am Dent Assoc* **75**, 1145–1166.
- 4) Hanson, M.L., Barnard, L.W. and Case, J.L. (1969). Tongue-thrust in preschool children. *Am J Orthod* **56**, 60–69.
- 5) Harris, J.E. and Kowalski, C.J. (1976). All in the family: Use of familial information in orthodontic diagnosis, case assessment, and treatment planning. *Am J Orthod* **69**, 493–510.
- 6) Klein, E.T. (1952). Pressure habits, etiological factors in malocclusion. *Am J Orthod* **38**, 569–587.
- 7) Kydd, W.L. and Neff, C.W. (1964). Frequency of deglutition of tongue thrusters compared to a sample population of normal swallowers. *J Dent Res* **43**, 363–369.
- 8) Kydd, W.L., Akamine, J.S., Mendel, R.A. and Kraus, B.S. (1963). Tongue and lip forces exerted during deglutition in subjects with and without an anterior open bite. *J Dent Res* **42**, 858–866.
- 9) Litton, S.F., Ackermann, L.V., Isaacson, R.J. and Spapiro, B.L.S. (1970). A genetic study of Class III malocclusion. *Am J Orthod* **58**, 565–577.
- 10) Ohno, T., Yogosawa, F. and Nakamura, K. (1981). An approach to openbite cases with tongue thrusting habits—With reference to habit appliance and myofunctional therapy as viewed from an orthodontic standpoint. Part One and Two. *Intern J Orofacial Myology* **7** (1), **7** (2), 3–10, 3–13.
- 11) Pierce, R.B. (1978). *Tongue Thrust, A Look at Oral Myofunctional Disorders*. pp.40–57, Cliffs Notes Inc., Nebraska.
- 12) Proffit, W.R., Chastain, B.B. and Norton, L.A. (1969). Linguopalatal pressure in children. *Am J Orthod* **55**, 154–166.
- 13) Proffit, W.R., Kydd, W.L. and Wilskie, G.H. (1964). Intraoral pressures in a young adult group. *J Dent Res* **43**, 555–562.
- 14) Saito, C. and Nojima, K. (1999). A cineradiographic study of the tongue movement on deglutition in malocclusion patients with low-tongue. *The Shikwa Gakuho* **99**, 33–55.
- 15) Subtelny, J.D. (1970). Malocclusion, orthodontic corrections and orofacial muscle adaptation. *Angle Orthod* **40**, 170–201.
- 16) Subtelny, J.D. and Subtelny, J.D. (1973). Oral habits—Studies in form, function, and therapy. *Angle Orthod* **43**, 347–383.
- 17) Suzaki, M., Naruse, M., Watanabe, N. and Yamaguchi, H. (2002). Measurement of lateral loads exerted on the maxillofacial region by habitual posture. *Bull Tokyo dent Coll* **43**, 69–74.

- 18) Takahashi, O., Iwasawa, T. and Takahashi, M. (1995). Integrating orthodontics and oral myofunctional therapy for patients with oral myofunctional disorders. *Intern J Orofacial Myology* **21**, 66-72.
- 19) Yamaguchi, H., Ohno, T., Sasaki, H., Zickefoose, W.E. and Zickefoose, J. (1998). *Clinic of Oral Myofunctional Therapy*. Wakaba Co., Tokyo.
- 20) Zickefoose, W.E. (1989). *Techniques of Oral Myofunctional Therapy*. O.M.T. Materials, Sacramento.
- 21) Zickefoose, W.E. (1980). *Oral Myofunctional Therapy, A Workbook for All Ages*. O.M.T. Materials, Sacramento.

Reprint requests to:

Dr. Hideharu Yamaguchi
Department of Orthodontics,
Tokyo Dental College,
1-2-2 Masago, Mihama-ku,
Chiba 261-8502, Japan