

# Glossoptosis (Posterior Displacement of the Tongue) During Sleep: A Frequent Cause of Sleep Apnea in Pediatric Patients Referred for Dynamic Sleep Fluoroscopy

Lane F. Donnelly<sup>1</sup>  
Janet L. Strife<sup>1</sup>  
Charles M. Myer III<sup>2</sup>

**OBJECTIVE.** The purpose of this study was to evaluate the frequency of glossoptosis (posterior displacement of the tongue) as a cause of sleep apnea in pediatric patients referred for fluoroscopic sleep studies.

**MATERIALS AND METHODS.** Seventy consecutive dynamic fluoroscopic sleep studies performed to evaluate sleep apnea were reviewed. All patients had been sedated and examined with lateral fluoroscopy during sleep. Anatomic changes in the airway were correlated with episodes of oxygen desaturation. Cases of glossoptosis, in which the tongue moved posteriorly during sleep and abutted the posterior pharynx, resulting in airway obstruction and oxygen desaturation, were identified. Associated factors were reviewed.

**RESULTS.** Of 70 sleep studies reviewed, glossoptosis was the cause of airway obstruction in 17 patients (24%). Mean age in these 17 patients was 3 years (range, 5 days to 13 years). Seven of the 17 children were younger than 1 year old. Only three patients had no underlying medical problems. Four patients had macroglossia (Down syndrome,  $n = 3$ ; duplicated tongue,  $n = 1$ ) as a cause, and three patients had micro- or retrognathia (Pierre Robin syndrome,  $n = 2$ ; Rubinstein-Taybi syndrome,  $n = 1$ ) as a cause. Six patients had neuromuscular abnormalities.

**CONCLUSION.** Glossoptosis was a cause of airway obstruction in 25% of pediatric patients referred for fluoroscopic sleep studies. Attention to this anatomic region is important when evaluating children with sleep apnea.

**A**pproximately 3% of all children are affected by obstructive sleep apnea syndrome [1, 2]. The most common cause of obstructive sleep apnea is enlarged adenoid and palatine tonsils, occurring in otherwise healthy children. However, underlying conditions predispose to other types of upper airways obstruction, often at multiple levels [3]. Although polysomnography is helpful in differentiating central versus obstructive causes of sleep apnea [4, 5], this imaging technique provides no accurate information concerning the anatomic level of obstruction in patients with obstructive sleep apnea. In patients with obstructive sleep apnea in whom a complicated medical history or persistent sleep apnea follows a surgical procedure performed to treat sleep apnea, dynamic sleep fluoroscopy has been shown to be a useful adjunct to endoscopic evaluation, affecting treatment decisions in greater than 50% of patients [3]. One potential cause of obstructive sleep apnea seen on dynamic sleep fluoros-

copy is glossoptosis, posterior movement of the tongue during sleep. This cause of airway obstruction has received little attention in the imaging literature. The purpose of this study was to evaluate the frequency of glossoptosis as a cause of sleep apnea in children referred for fluoroscopic sleep studies.

## Materials and Methods

Seventy consecutive dynamic fluoroscopic sleep studies performed to evaluate sleep apnea were reviewed. Cases in which the tongue moved posteriorly (glossoptosis) during sleep and abutted the posterior pharynx, resulting in airway obstruction and oxygen desaturation, were identified. All studies were performed for clinical reasons. Indications for evaluation with dynamic sleep fluoroscopy included the following: persistent symptoms of sleep apnea despite normal findings on flexible fiberoptic laryngoscopy, persistent symptoms of sleep apnea after a single site of obstruction was identified and appropriately treated, potential for obstruction at more than one site in the upper airways because of either previous surgery or an un-

Received May 8, 2000; accepted after revision May 31, 2000.

<sup>1</sup>Department of Radiology, Children's Hospital Medical Center, 3333 Burnet Ave., Cincinnati, OH 45229-3039. Address correspondence to L. F. Donnelly.

<sup>2</sup>Division of Otolaryngology, Children's Hospital Medical Center, Cincinnati, OH 45229-3039.

AJR 2000;175:1557-1557

0361-803X/00/1756-1557

© American Roentgen Ray Society

derlying abnormality, and difficulty decannulating a patient after tracheotomy.

All studies were performed and monitored by a pediatric radiologist. Patients were prepared for the procedure according to our departmental sedation program guidelines [6]. During the procedure a radiologist, radiology technologist, and radiology nurse were present. During the entire procedure and sedation recovery, respiratory rate, heart rate and rhythm, and blood oxygen saturation were monitored with transcutaneous pulse oximetry. The children were imaged in supine position with lateral fluoroscopy. Fluoroscopic findings were correlated with episodes of oxygen desaturation or noisy breathing. Fluoroscopic evaluation was performed for approximately 10–20 sec at areas of anatomic interest when signs of airway occlusion occurred. To limit the radiation dose, a maximum of 2 min of total fluoroscopic time was used. All studies were performed safely without complication.

Glossoptosis was defined as an abnormal posterior motion of the tongue that was associated with oxygen desaturation and noisy breathing (Figs. 1 and 2). In the healthy sleeping child, there is little or no motion of the tongue, pharynx, or trachea [7, 8]. With glossoptosis, the tongue falls posteriorly during sleep, abutting the velum (soft palate) and posterior

wall of the pharynx, and obstructs the airway (Figs. 1 and 2). The posterior pharyngeal wall remains in a stationary position. Glossoptosis was differentiated by fluoroscopic criteria from another cause of airway obstruction, pharyngeal collapse. With pharyngeal collapse, the anterior wall of the pharynx moves posteriorly, and the posterior wall of the pharynx moves anteriorly. This condition differs from glossoptosis in which only the tongue moves posteriorly. With pharyngeal collapse, the posterior pharyngeal wall, velum, and tongue oppose each other causing naso- and oropharyngeal obstruction.

All cases that met the criteria for glossoptosis were identified. Patient age and associated conditions were recorded.

### Results

Of 70 sleep studies reviewed, 17 (24%) met the criteria for glossoptosis as the cause of airway obstruction. Mean age in these patients was 3 years old (age range, 5 days to 13 years). Seven of the 17 children were younger than 1 year old. Of the 17 patients, 10 were boys and seven, girls.

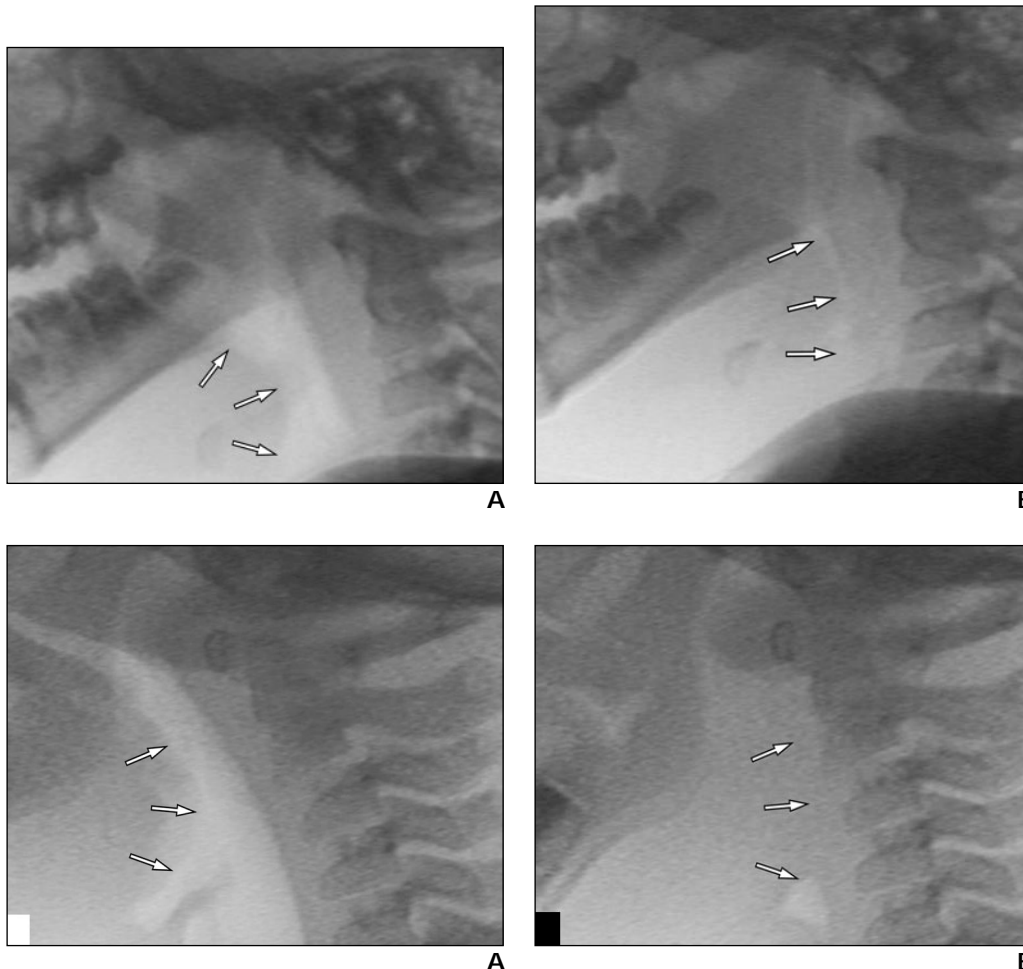
Associated abnormalities were the following: underlying congenital craniofacial abnor-

malities in seven, (Down syndrome in 3, Pierre Robin syndrome in 2, Rubinstein-Taybi syndrome in 1, and Pfeiffer's syndrome in 1). Four patients had macroglossia (Down syndrome,  $n = 3$ ; duplicated tongue,  $n = 1$ ) as a cause, and three patients had micro- or retrognathia (Pierre Robin syndrome,  $n = 2$ ; Rubinstein-Taybi syndrome,  $n = 1$ ) as a cause. However, in these patients the major contributor to obstructive apnea during sleep was the posterior motion, rather than enlargement or initial posterior position, of the tongue. Six patients had neuromuscular abnormalities (Fig. 1). Only three patients had no underlying medical problems.

Eight patients had previous surgery related to their airway symptoms. Three patients had previous adenoidectomies, four patients had previous tracheotomies, and one patient had a previous epiglottis repair.

### Discussion

Much of the literature that deals with sleep apnea in children has been focused on the use of



**Fig. 1.**—Glossoptosis in 1-year-old girl with cerebral palsy.

**A.** Video-captured fluoroscopic image shows air in posterior pharynx between base of tongue (arrows) and posterior wall of pharynx.

**B.** Video-captured fluoroscopic image obtained during episode of oxygenation desaturation shows tongue to have moved posteriorly. Posterior base of tongue (arrows) abuts posterior wall of pharynx, obstructing airway.

**Fig. 2.**—Glossoptosis in 3-year-old boy with duplicated tongue.

**A.** Video-captured fluoroscopic image shows air in posterior pharynx between base of posterior tongue (arrows) and posterior wall of pharynx.

**B.** Video-captured fluoroscopic image obtained during episode of oxygenation desaturation shows posterior tongue to have moved posteriorly. Posterior base of tongue (arrows) abuts posterior wall of pharynx, obstructing airway.

## Dynamic Sleep Fluoroscopy in Sleep Apnea

polysomnography in differentiating central and obstructive causes of sleep apnea [4, 5]. In contrast, there has been little focus on the use of dynamic fluoroscopic evaluation of children with obstructive sleep apnea [3, 8, 9]. Dynamic sleep fluoroscopy has been shown to be a useful adjunct to endoscopic evaluation in the workup of children who are predisposed to airway obstruction at multiple sites [3]. Children at risk for potential airways obstruction at multiple sites include those with congenital craniofacial anomalies [3], Down syndrome [10, 11], neuromuscular disorders [12], and metabolic storage diseases [13]. Previous airways surgery can also complicate the diagnostic evaluation of a child with obstructive sleep apnea [14, 15]. The cause of the airway obstruction may be related to recurrence of the primary cause originally treated with surgical intervention or may be a sequela of the surgical intervention itself [3, 14, 15]. Under such circumstances, findings on sleep fluoroscopy have been shown to alter the course of patient therapy in 52% of children [3].

In our series of children studied with dynamic sleep fluoroscopy, glossoptosis, shown in one fourth of patients, was one of the most common causes of airway obstruction. Glossoptosis has been most commonly described in children with micrognathia, particularly Pierre Robin syndrome [16, 17]. However, micrognathia was present in only three of the 17 patients in this series. Glossoptosis can occur in children with other associated anomalies. Hypotonia of the pharyngeal and glossal musculature can result in glossoptosis in children with neurologic impairment, as in six of our patients. In children with Down syndrome, airway obstruction can occur at the level of the tongue as a result of macroglossia, hypopharyngeal collapse, or glossoptosis [3, 10, 11]. In our series, three of the patients with glossoptosis also had Down syndrome.

It is particularly important to be aware of glossoptosis as a potential cause of airway obstruction in patients with Down syndrome or neurologic impairment because unless the glossoptosis is also addressed, sleep apnea may persist after surgery performed to alleviate other causes of airway obstruction. In eight of our patients, glossoptosis was identified only after surgery directed at other causes of airway obstruction failed to eliminate obstructive sleep apnea. Potential treatments for glossoptosis include noninvasive therapies such as the use of positive airways pressure devices [18]. Surgical interventions to either reduce the volume of the tongue or reposition the mandible have been described for patients refractory to medical treatment [17, 19].

In conclusion, we found glossoptosis to be a cause of airway obstruction in 25% of pediatric patients referred for fluoroscopic sleep studies. Attention to this anatomic region is important when evaluating children with sleep apnea, particularly children who are predisposed to potential causes of airway obstruction at multiple levels and in whom glossoptosis may be more apt to be overlooked.

### References

1. Brouillette RT, Fernbach SK, Hunt CE. Obstructive sleep apnea in infants and children. *J Pediatr* **1982**;100:31-40
2. Owens J, Opipari L, Nobile C, Spirito A. Sleep and daytime behavior in children with obstructive sleep apnea and behavioral sleep disorders. *Pediatrics* **1998**;102:1178-1184
3. Gibson SE, Myer CM III, Strife JL, O'Connor DM. Sleep fluoroscopy for localization of upper airway obstruction in children. *Ann Otol Rhinol Laryngol* **1996**;105:678-683
4. Rosen CL. Clinical features of obstructive sleep apnea hypoventilation syndrome in otherwise healthy children. *Pediatr Pulmonol* **1999**;27:403-409
5. Coleman J. Disordered breathing during sleep in newborns, infants, and children: symptoms, diagnosis, treatment. *Otolaryngol Clin North Am* **1999**;32:211-222
6. Egelhoff HC, Ball WS, Koch BL, Parks TD. Safety and efficacy of sedation in children using a structured sedation program. *AJR* **1997**;168:1259-1262
7. Ardran GM, Kemp FH. The nasal and cervical airway in sleep in the neonatal period. *AJR* **1970**;108:537-542
8. Felman AH, Loughlin GM, Leftridge CA Jr, Casisi NJ. Upper airway obstruction during sleep in children. *AJR* **1979**;133:213-216
9. Smith TH, Baska RE, Francisco CB, McCray GM, Kunz S. Sleep apnea syndrome: diagnosis of upper airway obstruction by fluoroscopy. *J Pediatr* **1978**;93:891-892
10. Jacobs IN, Gray RF, Todd NW. Upper airway obstruction in children with Down's syndrome. *Arch Otolaryngol Head Neck Surg* **1996**;9:945-950
11. Marcus CL, Keens TG, Bautista DB, von Pechmann WS, Ward SL. Obstructive sleep apnea in children with Down syndrome. *Pediatrics* **1991**;88:132-139
12. Arnold JE, Allphin AL. Sleep apnea in the neurologically-impaired child. *Ear Nose Throat J* **1993**;72:80-81
13. Myer CM III. Airway obstruction in Hurler's syndrome: radiographic features. *Int J Pediatr Otorhinolaryngol* **1991**;22:91-96
14. Guillemainault C, Korobkin R, Winkle R. A review of 50 children with obstructive sleep apnea. *Lung* **1981**;159:275-287
15. Hoeve LJ, Rombout J. Pediatric laryngobronchoscopy: 1332 procedures stored in a data base. *Int J Pediatr Otorhinolaryngol* **1992**;24:73-82
16. Cozzi F, Pierno A. Glossoptosis-apnea syndrome in infancy. *Pediatrics* **1985**;75:836-843
17. Rodriguez JC, Dogliotti P. Mandibular distraction in glossoptosis-micrognathic association: preliminary report. *J Craniofac Surg* **1998**;9:127-129
18. Bower CM, Ganger A. Pediatric obstructive sleep apnea syndrome. *Otolaryngol Clin North Am* **2000**;33:49-75
19. Chabolle F, Wagner I, Blumen MB, Sequert C, Fleury B, De Dieuleveult T. Tongue base reduction with hyoepiglottoplasty: a treatment for severe obstructive sleep apnea. *Laryngoscope* **1999**;109:1273-1280

